

Gas Bubble Disease (GBD)

I. Causative Agent and Disease

Gas bubble disease is not infectious and is caused by supersaturated levels of total dissolved gas in the water. Lesions in the fish are caused by the accumulation of gas bubbles in blood vasculature and tissues. Either supersaturation of oxygen or nitrogen can result in the disease, however, the total dissolved gas (TDG) is more important than individual gases or varying combined gas ratios. Supersaturation occurs when water contains more dissolved gas than it can normally hold in solution at a given temperature and atmospheric pressure. Under high pressure or at low temperatures water can contain more gas. Gas supersaturation in water can occur from both natural and artificial causes. In nature, supersaturation occurs in plunge pools at the base of waterfalls, in natural springs and wells where water is under pressure at depth, and in water that has melted from glaciers or snow. During the photosynthetic process water bodies containing heavy aquatic plant growth can be saturated with oxygen and can become supersaturated upon warming. Artificially supersaturated water occurs in plunge pools from dams, when water is heated such as power plant effluent, and if air is entrained in pipes or pumps where pump pressure or gravity head forces gas into solution.

II. Host Species

The disease can affect any fish or invertebrate anywhere when in supersaturated waters. Levels of gas supersaturation causing pathological changes or mortality vary for different fish species and age of fish. Fry become susceptible post-hatch when they begin swimming up for food (at about 16 days). Steelhead trout are most sensitive (average thresh

old of 102-103% TDG before chronic problems develop) while coho salmon are least sensitive (average threshold 115.7% TDG)

III. Clinical Signs

Fish with GBD often exhibit loss of equilibrium, abnormal buoyancy and may float at the water surface. Fish may also exhibit violent head shaking, convulsions, flared opercula, release of excessive gas from buccal cavity, blindness and may die with the mouth open. Alevins may show hemorrhage of vitelline vessels, rupture of yolk-sac membranes, and coagulated yolk. Subcutaneous bubbles can accumulate in tissues of the head, mouth, fin rays, and gill arches. Air bubbles are often visible in gill lamellar capillaries. Hemorrhage of gills, fins, skin, muscle, gonads, and intestinal epithelium can also occur. Fins may be eroded with whitened fin tips and exophthalmia may occur with blood present in the anterior chamber of eye.

TDG

- 100-106% Embolic lesions will appear with hemostasis
- ≥ 103% Certain species of salmonid fry are stressed and may later develop conditions leading to death (i.e., coagulated yolk, fin erosion, tail erosion, etc.)
- > 120% Acute levels, fry will die before signs or lesions indicate a problem

IV. Transmission

Due to the environmental nature of this disease, transmission between fish does not occur.

V. Diagnosis

Diagnosis is made by the observation of typical clinical signs and lesions. The presence of gas emboli in capillaries of the gills, fin rays, mouth and eyes are diagnostic.

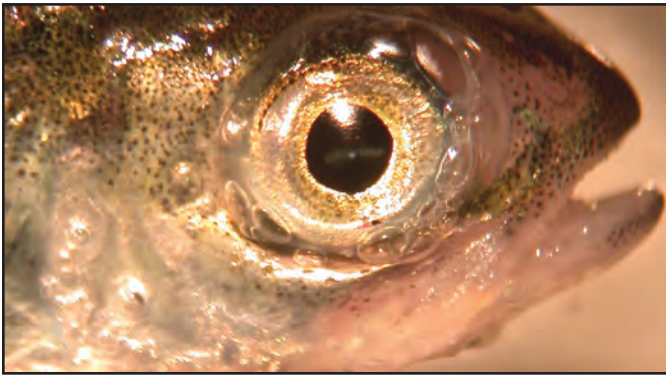
VI. Prognosis for Host

Gas bubble disease often results in chronic low-level fish mortality, especially in a hatchery environment. In natural waters, fish exposed to high TDG's will seek greater depth or cooler

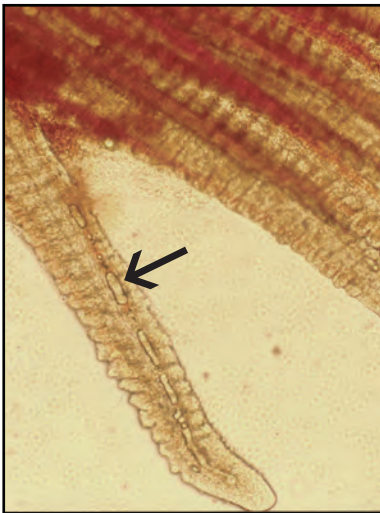
waters where gas saturation is lower. There is no evidence that gas supersaturation adversely affects hatching success of salmonid embryos. GBD can be the underlying cause of various diseases by predisposing fish to other secondary bacterial, viral or protozoan infections that must be differentiated first before determining the primary problem.

VII. Human Health Significance

There are no human health concerns associated with GBD in fish.



Visible gas bubbles in connective tissues of operculum and eye typical of acute gas bubble disease.



Left: Gas bubbles (arrow) trapped in capillaries of a gill lamella typical of gas bubble disease; **Right:** Gas bubbles in and around connective tissue of the mouth.