

Fungal Infection of Captive Red King Crabs

I. Causative Agent and Disease

An unidentified marine fungus caused mortality of four captive adult red king crabs producing a disease characterized by carapace discoloration of the walking legs and multiple granulomas and necrosis in the underlying epidermal and sub-epidermal tissues. There are no other known reports in the literature of a similar fungus infection in adult red king crabs. Whether the fungus infection occurs in wild crabs or is related to the stress and environment of captivity is not known.

II. Host Species

The fungus occurred in captive adult red king crabs collected from Cook Inlet, Alaska, but other crab species may be susceptible.

III. Clinical Signs

Focal yellow-brown discoloration appears on the carapace of walking legs followed by deep necrotic ulceration of the underlying soft tissues, loss of affected legs and crab mortality. The lesions are localized and not systemic characterized histologically by severe hemocyte infiltration and granulomas forming around fungal hyphae.

IV. Transmission

The mode of transmission is unknown but assumed to be horizontal within the water column, probably requiring an injury to the carapace as a portal of entry.

V. Diagnosis

Diagnosis is by observation of typical focal discolorations of the carapace (see similar lesions in shell disease section) followed with histological confir-

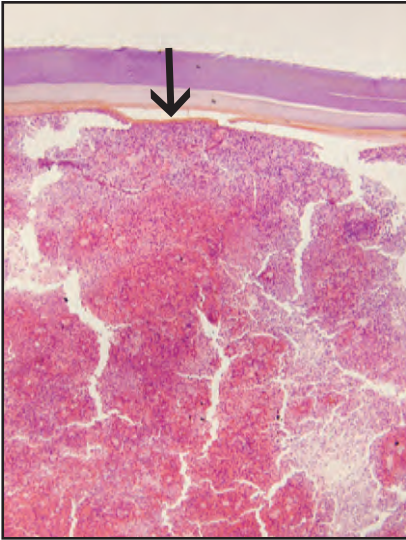
mation of granuloma formation around branching aseptate fungal hyphae that are positive (black) when stained with Grocott's method of methenamine-silver nitrate (GMS) for fungi. An opportunity for further characterization of the fungus by attempted isolation on artificial media has not occurred.

VI. Prognosis for Host

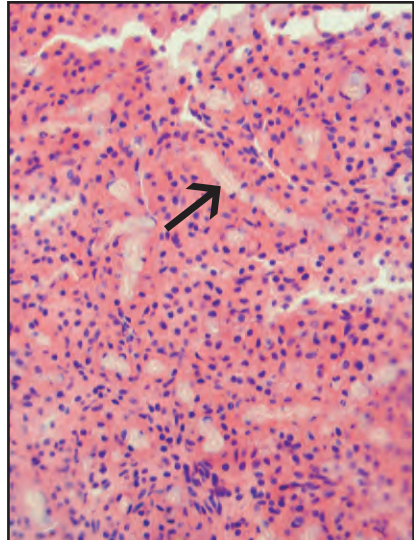
This fungal infection of the carapace results in deep localized invasion of underlying soft tissues, secondary bacterial infection, leg loss and crab mortality. Even minor shell damage may result in adhesion of the old carapace to the site of the wound during molting causing incomplete ecdysis and mortality of the crab. Whether this fungus occurs in wild populations of king crabs or is an artifact of captivity is not known.

VII. Human Health Significance

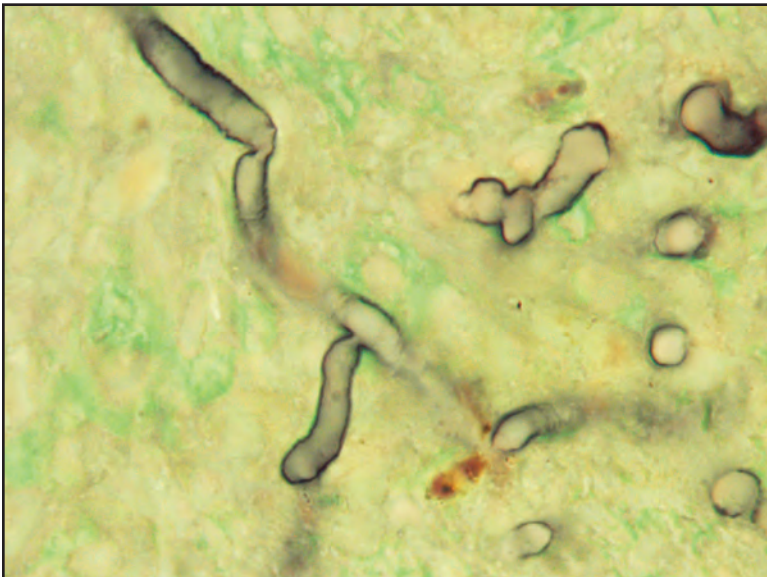
Although unsightly, this fungal infection of captive red king crabs is unlikely to have any zoonotic significance for human health.



Histological section of fungal hyphae within localized granuloma (arrow) in soft tissues beneath the carapace of infected red king crab



Higher magnification of granuloma and fungal hyphae (arrow)



GMS stain of aseptate fungal hyphae (black) from figures above